

## Case Definition: Stony Coral Tissue Loss Disease (SCTLD)

October 2, 2018

**Highly Susceptible Species:** Early onset (the species first affected during an outbreak), rapid progression, and total mortality ranging from one week for smaller colonies to complete mortality over 1-2 months for larger colonies. Typically, *M. meandrites* and *D. stokesii* are the first to become affected at a site, followed by *C. natans*, and then the others show disease signs shortly thereafter.

*Colpophyllia natans* (boulder brain coral)

*Dendrogyra cylindrus* (pillar coral)\*

*Dichocoenia stokesii* (elliptical star coral)

*Diploria labyrinthiformis* (grooved brain coral)

*Eusmilia fastigiata* (smooth flower coral)

*Meandrina meandrites* (maze coral)

*Pseudodiploria strigosa* (symmetrical brain coral)

*Pseudodiploria clivosa* (knobby brain coral)

**Intermediately Susceptible Species:** Onset of tissue loss typically occurs about a month after onset in highly susceptible species, but lower numbers may also show disease signs before or as those species are affected. Smaller colonies die out over months, and larger colonies may show new lesions continuing with possible mortality occurring over years.

*Orbicella annularis* (lobed star coral)\*

*Orbicella faveolata* (mountainous star coral)\*

*Orbicella franksi* (boulder star coral)\*

*Montastraea cavernosa* (large-cup star coral)

*Solenastrea bournoni* (smooth star coral)

*Stephanocoenia intersepta* (blushing star coral)

*Siderastrea siderea* (starlet coral)\*\*

\*\* *S. siderea* may show disease signs before highly susceptible species, during outbreaks, and after the outbreak has progressed through a reef system. The presentation of disease may be similar to SCTLD in some but not all cases, and the epidemiology, e.g., the patterns of lesion spread within and among colonies and duration of tissue loss, does not always match those of other species. This raises some uncertainty about inclusion of *S. siderea* in this case definition.

**Presumed Susceptible but insufficient data to categorize onset.**

*Agaricia agaricites* (lettuce coral)

*Agaricia* spp. (plate/saucer corals)

*Mycetophyllia* spp. (cactus coral)

*Madracis arenterna* (pencil coral)

*Favia fragum* (golfball coral)

*Helioseris cucullata* (sunray lettuce coral)

*Mussa angulosa* (spiny flower coral)

*Scolymia* spp. (disc coral)

*Isophyllia* spp. (sinuous cactus coral; rough star coral)

**Low Susceptible Species:** During outbreaks, the following corals are rarely or not affected.

*Porites astreoides* (mustard hill coral)

*P. porites* (finger coral)

*P. divaricata* (thin finger coral)

*P. furcata* (branched finger coral)


*Acropora palmata* (elkhorn coral)\*

*A. cervicornis* (staghorn coral)\*

*Oculina* spp. (bush corals)

*Cladocora arbuscula* (tube coral)

\*Endangered Species Act (ESA) listed species



**Fig. 1.** SCTLD in *P. strigosa* (top left), *D. labyrinthiformis* (top right), *C. natans* (2<sup>nd</sup> row, left), *P. clavosa* (2<sup>nd</sup> row right), *M. cavernosa* (3<sup>rd</sup> row left), *D. stokesii* (3<sup>rd</sup> row right), *S. siderea* (bottom left), *O. annularis* (bottom right). Images: Looe Key, August 2018, A. Bruckner, FKNMS

## **Gross Morphology**

Focal, multifocal, locally extensive to diffuse areas of acute to subacute tissue loss distributed basally, peripherally, or both. In some cases, tissues bordering areas of chronic tissue loss have indistinct bands (1–5 cm) of pallor progressing to normal pigmentation away from denuded skeleton.

Non-technical description: Tissue loss often appears initially on the edge of the colony and spreads upwards and is characterized by newly exposed white intact skeleton that can become covered with algae within 3–7 days. Tissue-loss lesions can also begin as patches or blotches within intact tissue that can increase in size and fuse together. Some species (especially *M. cavernosa*) may have bleached tissues adjacent to the tissue-loss lesion. For *S. siderea*, one or more areas of dark discoloration may be present in remaining tissue at the same time as tissue loss.

## **Morphologic Diagnosis**

Focal to diffuse acute to subacute tissue loss with or without simultaneous paler or darker tissue discoloration

## **Histology**

Preliminary data for *M. cavernosa* indicates that tissue pathology first affects the basal body wall (BBW) gastrodermis and progresses towards the oral surface of the tissue (polyps and coenenchyme), presenting as a surface lesion. Variable numbers of zooxanthellae manifest pyknosis, cytoplasmic hypereosinophilia, and symbiosome enlargement and vacuolation. Gastrodermal tissue necrosis is associated with degradation and fragmentation, swelling, and disintegration of the mesoglea. In some specimens (diseased and unaffected areas from the same colony), crystalline inclusion bodies (CIBs) are found mostly in the BBW gastrodermis and occasionally in the surface BBW gastrodermis. Gastrodermis in areas with CIBs can be vacuolated and the BBW calicodermis may be detached from the mesoglea. CIBs are also seen adjacent to lysed lesion margins along the BBW.

## **Etiologic Diagnosis**

Unknown

## **Etiologic Differentials (possible causes to consider):**

- Bacterium
- Virus
- Toxin (potential initiating agent that weakened coral and increases susceptibility to bacterium)
- Toxicant
- Metabolic dysfunction

## Epidemiology/Pathogenesis

### A. Antibiotic treatments

Antibiotic treatments with amoxicillin, kanamycin and ampicillin (separately and in combination) and triple antibiotic compound (bacitracin, neomycin, and polymyxin) have been tested in small scale mesocosm and field studies in *D. cylindrus*, *D. stokesii*, *M. meandrites*, *C. natans*, *P. strigosa*, *M. cavernosa*, *D. labyrinthiformis*, *S. siderea* and *O. faveolata*. In *M. cavernosa* disease was stopped in 8 of the 9 sets when treated with amoxicillin and kanamycin (50 µg/ml sea water of each placed directly in the tank; Paul, Aeby, Häse and Ushijima 2017).

Treatment Condition	Coral ID	Condition after initial treatment 8/12/2016	Contracted "Brown Jelly"	Additional Treatments* 8/15-9/27	Condition on 8/24/2016	Condition on 10/25/2016
100% Water change only	PCF-39	visibly diseased	no	3	DEAD	DEAD
	TR2-25	visibly diseased	no	2	recovering	recovered
	TR2-56	visibly diseased	no	3,1	recovering	recovered
	E7-41	DEAD	DEAD	DEAD	DEAD	DEAD
	E7-43	visibly diseased	no	2,6	visibly diseased	recovered
Lugol's dip T0 and T24 h	PCF-33	DEAD	DEAD	DEAD	DEAD	DEAD
	TR2-35	slowed disease	yes	1,5,4	recovering	recovered
	E7-42	slowed disease	yes	1,5,4	recovering	recovered
	LKLD1-73	slowed disease	yes	1,5,4	recovering	recovered
	E7-92	visibly diseased	no	3	DEAD	DEAD
100 mg/L Ampicillin	PCF-40	DEAD	DEAD	DEAD	DEAD	DEAD
	PCF-38	slowed disease	yes	4	recovering	recovered
	TR2-32	visibly diseased	no	DEAD	DEAD	DEAD
	TR2-55	visibly diseased	yes	4	recovering	recovered
	E7-53	visibly diseased	yes	1,4,6	recovering	DEAD
100 mg/L Paromomycin	PCF-37	slowed disease	yes	1,7,5,4	visibly diseased	recovered
	TR2-34	slowed disease	yes	1,7,5,4	recovering	recovered
	TR2-65	DEAD	DEAD	DEAD	DEAD	DEAD
	E7-60	slowed disease	yes	1,7,5,4	recovering	DEAD
	E7-91	slowed disease	yes	1	DEAD	DEAD

**Table 1. Laboratory treatment of diseased *Dendrogyra cylindrus*.** Corals were treated using a variety of methods initially (as described in column 1). In some cases, the disease slowed following the initial treatment, in others there was no change or the corals died. A portion of the colonies later succumbed to brown jelly following initial treatment. Subsequent treatments (column 5) and fates of corals over the following months are shown in column 6 and 7.

\*Additional Treatment Key:

<sup>1</sup>Amoxicillin (60-65 mg in dental paste) was applied at the disease margin

<sup>2</sup>Ampicillin (100 mg/L in artificial seawater) for 10 days

<sup>3</sup>CVS Triple antibiotic ointment applied at disease margin (400 U bacitracin, 3.5 mg neomycin, 5000 U polymyxin B)

<sup>4</sup>Fragmented coral ahead of disease margin, 15 min Lugol's dip followed by 100 mg/L ampicillin for 7 days

<sup>5</sup>Bayer Advanced Complete Insect Killer (50 mg/L) for 15 min, rinsed and placed in clean tank with ASW

<sup>6</sup>Amoxicillin (0.4 mL of 40 mg/mL in dental paste) applied to disease margin

<sup>7</sup>Paromomycin (65 mg in 1.5 mL dental paste) applied to disease margin.

Source of data: Cheryl Woodley.

Species	Treatment	# Treated	# FAILED (4 weeks)	% Failure (4 weeks)
DCYL	Trench + Base2+ Amoxi	22	3	14%
	Trench + Shea Butter + Amoxi	5	0	0%
	NO trench + Base2 + Amoxi	12	1	8%
	NO trench + Shea Butter + Amoxi	4	1	25%
OFAV	Trench + Amoxi	3	0	0%
	No trench + Amoxi	3	0	0%
CNAT	Trench + Amoxi	5	0	0%
	No trench + Amoxi	2	0	0%
PSTR	Trench + Amoxi	1	0	0%
DLAB	Trench + Amoxi	1	0	0%
SSID	No trench + Amoxi	1	1	100%
MCAV	No trench + Amoxi	2	0	0%

**Table 2. Summary of antibiotic field trials in the Middle Florida Keys using amoxicillin.** All colonies were followed for a minimum of four weeks after treatment. Source of data: Karen Neely, NOVA Southeastern University.

Species	Treatment	# Treated	# slowed	# recovered
MCAV	amoxicillin & kanamycin	13	1	12 (92%)
MMEA	amoxicillin & kanamycin	3		3 (100%)
CNAT	nalidixic acid	8	3 (37.5%)	2 (25%)

**Table 3. Summary of antibiotic laboratory trials using corals from Fort Lauderdale, Florida.** Source of data: Greta Aeby.

## B. Transmission studies

Based on limited mesocosm studies, subacute tissue-loss gross lesions can appear in unaffected coral through direct and indirect contact with diseased coral from *M. cavernosa* to *M. cavernosa* and *M. cavernosa* to *Orbicella faveolata*, but direct and indirect contact of *M. cavernosa* to *P. astreoides* did not result in lesions. *C. natans* with acute tissue-loss lesions elicited lesions in apparently healthy *M. cavernosa* and *M. meandrina* by touching and non-touching. Differences among pathogen transmission may be noted depending on source of affected colonies and the state of the lesion (e.g., a newly appearing lesion vs. an older one), and between species, with more tests needed for certain species (e.g., *S. siderea*).

Diseased Coral No.	Diseased coral	Unaffected coral	No. trials	Transmission (direct contact)	Transmission (not-touching)
1	<i>M. cavernosa</i>	<i>M. cavernosa</i>	10	3 (30%)	1 (10%)
1	<i>M. cavernosa</i>	<i>O. faveolata</i>	10	10 (100%)	4 (40%)
2	<i>M. cavernosa</i>	<i>M. cavernosa</i>	8	2 (25%)	0 (0%)
2	<i>M. cavernosa</i>	<i>P. astreoides</i>	8	0 (0%)	0 (0%)
3	<i>C. natans</i>	<i>M. cavernosa</i>	10	10 (100%)	6 (60%)
3	<i>C. natans</i>	<i>M. meandrina</i>	10	10 (100%)	10 (100%)

**Table 4. Summary of transmission trials.** Diseased corals were fragments taken from the same coral (e.g. Diseased Coral No. 1 was subdivided for the trials listed in row one and two) to compare transmission to other species and via direct and indirect transmission. Source of data: Greta Aeby and Valerie Paul, Smithsonian Marine Station.

## C. Patterns of disease spread, tissue loss and prevalence

### Disease spread

In the field, tissue-loss lesions appeared to spread north and south from the putative epicenter identified in 2014 off Virginia Key near Miami, to the northernmost extent of the Florida reef tract (FRT) and south into the lower Florida Keys at a rate of 7–10 km per month during 2015–2017. The disease first emerged in the Lower Keys near Looe Key in April 2018 and spread since this time appears to have slowed to about 2.5 km per month. As of 09/15/18 the disease is currently approximately 5 miles from Looe Key, and is primarily only on the outer reef tract, with inner and middle shelf reefs within the Lower Keys not showing signs of SCTLD.

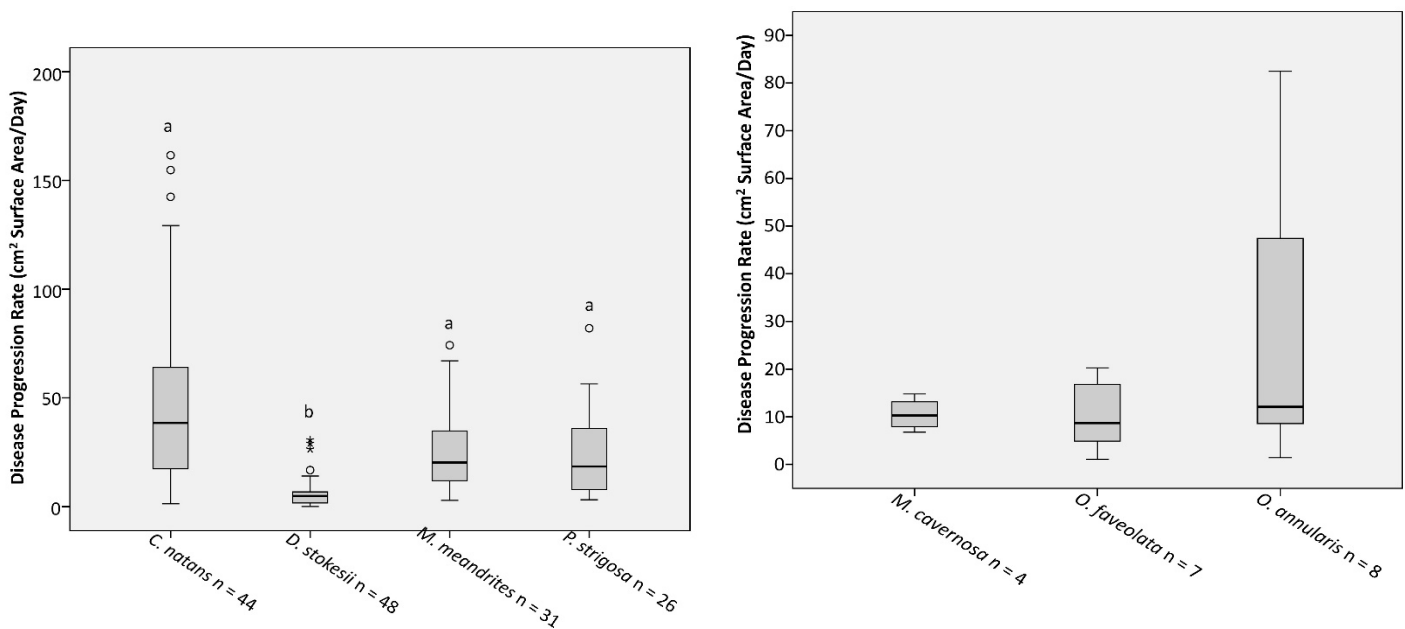
### Rates of tissue loss

In aquaria, linear tissue loss advanced at maximum rates of 3 cm/day in *C. natans* and *P. strigosa*, and 4 cm /day in *D. stokesii* and *M. meandrina*. In the field, tissue loss on individual tagged colonies varied by region, time of year, coral species, and among individual colonies of the same species. In some colonies the disease resulted in complete mortality, but in others, tissue loss progressed much more slowly and even halted on some individuals. Variations in rates and extent of tissue loss have also been observed for different lesions on the same colony. In some cases, multiple lesions coalesce and continue to advance, while others halt after variable amounts of time. Further, some corals survived after an initial lesion appeared but stopped enlarging, then new lesions appeared at a later date, which may be the result of exposure to the same or different causative agent(s). Some corals have also exhibited simultaneous signs of multiple diseases (e.g., yellow blotch, black band, dark spots, and SCTLD).

## Prevalence and tissue loss

Species	N	No Disease		Disease		Partial colony mortality		Complete Colony Mortality	
		N	%	N	%	N	%	N	%
<i>C. natans</i>	97	12	12%	85	88%	56	58%	29	30%
<i>D. stokesii</i>	86	12	14%	74	86%	43	50%	31	36%
<i>D. labyrinthiformis</i>	10	5	50%	5	50%	3	30%	2	20%
<i>M. meandrites</i>	24	0	0%	24	100%	12	50%	12	50%
<i>P. strigosa</i>	48	7	15%	41	85%	27	56%	14	29%
<i>P. clivosa</i>	3	0	0%	3	100%	1	33%	2	67%
<i>M. cavernosa</i>	107	60	56%	47	44%	38	36%	9	8%
<i>O. faveolata</i>	29	13	45%	16	55%	16	55%	0	0%
<i>S. intersepta</i>	258	131	51%	127	49%	125	48%	2	1%

**Table 5.** Pooled data from four Florida FWC sentinel sites in the middle Keys summarizing colony status from December 2017 through mid-August 2018. The incidence of disease had largely leveled off by July. Source of data: Bill Sharp, FWC.



**Fig. 2.** Rate of tissue loss per day within four Florida FWC sentinel sites in the middle keys from December 2017 through mid-August 2018. Source of data: Bill Sharp, FWC.

## Distinctive gross morphologic features that differentiate other diseases in corals susceptible to SCTLD

**White plague:** Lesions are focal or multifocal-to-coalescing, with a linear or annular margin, depending on colony morphology. Tissue adjacent to exposed skeleton may be bleached. Linear tissue loss begins at the base or margin of a colony or emanates from an algal/sediment interface within the colony, and advances 1 mm to > 10 cm/day. Three types have been reported, primarily based on affected species and rates of spread within individual affected colonies. Affects up to 40 species of Western Atlantic corals. Photo: Florida Keys, 1995 Andrew Bruckner



*Gross morphologic features of white plague are most similar to SCTLD in that:*

- 1) there appears to be variability in the rate of tissue loss within and among affected species
- 2) it can start at the base or margin of the coral and radiate out in a distinct band,
- 3) colonies exhibit rapid tissue loss
- 4) no microbial biomass is observed at the tissue loss margin
- 5) an area of bleached tissue up to 3-mm wide at the edge of the lesion (tissue-loss margin) may be present
- 6) most of the same species are susceptible

Gross morphologic features of white plague are different from SCTLD in that:

- 1) Lesions may appear within the remaining tissue of colonies in SCTLD (in the middle of the colony) as opposed to usually starting at the margin or base of colonies affected with white plague

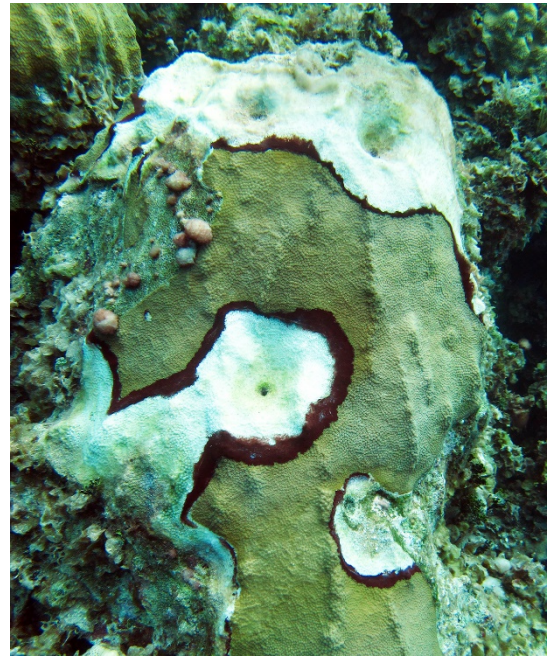
### *Other notable differences*

- SCTLD has continued to spread throughout the reef tract for four years, and the pathogen is presumably transmitted primarily via water currents (although other vectors may be involved) white plague outbreaks tend to be more short lived
- outbreaks of white plague tend to occur in restricted areas but often appear on multiple reefs at the same or a different time
- white plague has emerged over extensive areas of reef tract in multiple countries simultaneously following other disturbances (e.g., following the 2005 bleaching event in Puerto Rico and the USVI).
- SCTLD has not, to date, shown seasonal patterns in tissue loss linked to warming or cooling ocean temperatures; white plague has subsided in winter months as temperatures cooled.
- SCTLD affects coral species in a specific order, with highly susceptible species showing initial signs, followed by intermediate susceptible species.



## Distinctive gross morphologic features that differentiate other coral diseases


**Black-band disease:** The key difference from SCTLD to black band disease is the presentation of a black or dark reddish-brown linear, diffuse or annular band of acute to subacute tissue loss with a 1-mm to 5-cm wide margin, less than 1-mm thick. Band is composed of black-red filamentous organisms mixed with white filaments, separating healthy tissue and white, bare skeleton. Band radiates outwards from the colony margin or a focal site of injury. Affects at least 22 species of Western Atlantic corals. Photo: Florida Keys, 1986 Andrew Bruckner



**Caribbean ciliate infection:** The key difference between Caribbean ciliate infection and SCTLD is the presentation of a diffuse black or grey band, several mm to 2-cm thick, separating healthy tissue from bare skeleton or the presence of a diffuse scattered patch composed of the black ciliate tests on recently exposed skeleton. Primarily affects acroporids; also seen on *Orbicella* and other species. Photo: Florida Keys, 2018 Andrew Bruckner

**Dark spots disease.** The key difference between dark spots disease and SCTLD is the presentation of focal to multifocal patches of discolored tissue or tissue-loss lesions with annular to irregular margins that are purple to brown in color and 1 cm to more than 45 cm in diameter. Dark spots may expand over time, coalesce, and form diffuse to annular bands adjacent to or surrounding exposed skeleton. Affected tissue may be associated with a depression of the coral surface as surrounding unaffected polyps and coenenchyme continue to produce skeleton and may seasonally disappear. Underlying skeleton may retain dark pigmentation when tissue is gone. Primarily affects *Stephanocoenia*, *Orbicella* and *Siderastrea*. In the last species, a pigmented fungus has been identified in the skeleton (endolithic hypermycosis) and differences in tissue microbial communities of diseased and normally pigmented tissue areas have been found in all affected species.

Top image: DSD, bleaching and tissue loss; lower image: DSD without tissue loss. Photos: Florida Keys, 2012 Andrew Bruckner



**Yellow blotch disease:** The key difference between yellow blotch disease and SCTLD is the presentation of focal or multifocal, diffuse lesions with annular to linear margins of pale yellow tissue, bordered by healthy tissue. Lesions progress mm to cm per month. The margin of the remaining tissue is always pale yellow or lemon colored, whereas previously affected tissue gradually darkens prior to full tissue loss; acute tissue loss (revealed by the presence of exposed skeleton at the lesion margin) is rare. Primarily affects *Orbicella*.



Top image: new YBD lesion affecting *O. annularis*; lower image: multiple YBD lesions affecting *O. faveolata*.  
Photos: Mona Island, Puerto Rico, 2001 Andrew Bruckner

